

## Colonic Hypoganglionosis: A Report of 2 Cases

Obeidat B<sup>1</sup>, Naseem H<sup>2</sup>, Obaid G<sup>3</sup> and Alotaibi AM<sup>4\*</sup>

<sup>1</sup>Department of Surgery, Dr. Samir Abbas Hospital, Jeddah, Saudi Arabia

<sup>2</sup>Department of surgery, King Abdelaziz Hospital, Makkah, Saudi Arabia

<sup>3</sup>Department of Surgery, King Abdullah Medical City, Makkah, Saudi Arabia

<sup>4</sup>Department of Surgery, Faculty of Medicine, University of Jeddah, Jeddah, Saudi Arabi, and Dr Soliman Fakeeh Hospital, Jeddah, Saudi Arabia

### 1. Abstract

Even though there are many neuromuscular disorders, if a surgeon sees a patient with nerve problems in the colon, he or she may think the person has Hirschprung's disease. Colonic hypoganglionosis is an uncommon disease that affects women more often than men. It is linked to delayed symptoms and has a more favorable outlook than Hirschprung disease. Full-thickness biopsy and immunohistochemistry are crucial for the final diagnosis since hypoganglionosis is hard to distinguish from other neurological disorders of the colon. Why having knowledge of this very unlikely case scenario may assist in improving clinical judgment, assisting in the treatment of patients, and accumulating evidence for such a dilemma. Two young patients with megacolon were described here, both of whom needed emergency surgery.

**2. Keywords:** Colonic Hypoganglionosis; Enteric neuromuscular disorder; Surgery; Constipation; Large bowel obstruction; Case report

### 3. Introduction

The very uncommon condition known as acquired or adult-onset Hypoganglionosis (HG) belongs to a category of diseases caused by defects in the intestinal neural system. Hirschsprung's Disease (HD), intestine neural dysplasia, and ganglioneuromatosis, and hypoganglionosis are all examples of these disorders. [1] Hypoganglionosis is more frequent in women and is associated with delayed symptoms and a better prognosis than HD. [2] Differentiating between them might be difficult since they all present with the same clinical pic-

ture: constipation or pseudoobstruction [1].

Congenital and acquired, type I and type II, isolated, and Hirschsprung-related are only some of the several ways that HG has been categorized in the scientific literature [2-4]. At birth, the congenital form's ganglion cells are few in number and tiny in size; whereas the acquired form's ganglion cells become larger with time, the former does not. By contrast, ganglion cell degeneration is the underlying cause of acquired HG, which manifests in late adulthood [1].

Type I and Type II hypoganglionosis are different because of how many ganglion cells are in the colonic plexuses and how they are spread out across the plexuses. In other words, severe ganglion loss only happens in a small area, while illness causes moderate ganglion loss all over the colon [2].

The only way that has been shown to reliably confirm the diagnosis is to do a full-thickness biopsy and immunohistochemical analysis [5]. Microscopic examination of patients with HG revealed hypertrophy of the muscularis mucosa, reduced acetylcholinesterase activity in the lamina propria, and a dramatic decrease in myenteric ganglia to an amount less than 10 mm in diameter [1]. Two patients with HG were reported; one of them also had esophageal achalasia. Both patients were managed at a private university hospital.

### 4. Presentation

#### 4.1. Case 1

Here, we'll talk about a 30-year-old woman who has recently been diagnosed with anxiety, bronchial asthma, and GI problems. After

\*Correspondence to: Abdulrahman Muaod Alotaibi, MD, Associate Professor, Department of Surgery, Faculty of Medicine, University of Jeddah, Jeddah, Saudi Arabia

Received date: Jan 26, 2026; Accepted date: Mar 21, 2026; Published date: Feb 26, 2026

Citation: Alotaibi AM (2026). Colonic Hypoganglionosis: A Report of 2 Cases. *Anna. Gynec. Reprod. Health Res.* 2026; v10(1): 1-5

Copyright: © 2026 Alotaibi AM. This is an open-access article distributed under the terms of the Creative Commons Attribution License, which permits unrestricted use, distribution, and reproduction in any medium, provided the original author and source are credited

complaining of recurrent vomiting and dysphagia for three years, a barium swallow and motility study were performed, leading to the diagnosis of achalasia. Her swallowing has improved after she received a Heller myotomy in December 2018. Subsequently, she had a weight loss of 30 kg, menstrual irregularity, dysuria, constipation, and abdominal distention. Her symptoms of abdominal distention were alleviated after repeated rounds of colonoscopic decompression. In June 2020, she came to the emergency room with abdominal pain (score 7/10), distention, and dysuria. Her blood pressure was 126/60, her heart rate was 123, and her temperature was 36.6. Respiratory Rate: 20, O<sub>2</sub> Saturation: 100%

Abdomen were distended, tympanic, no peritonitis sign. Laboratory finding: WBC 12 x 10<sup>3</sup>/ul, CRP: 17.7 mg/l, Hb: 10.2 g/dl, albumin: 3.2 g/dl, lactic acid: 0.8 mmol/l, potassium: 3.1 mmol/l. Other lab results, including liver function tests, thyroid function tests, renal functions, and serum electrolytes, were within normal limits. Stool and urine cultures were unexceptional. An abdominal x-ray showed a dilated bowel with no air under the diaphragm. The computed tomography revealed a 12 cm-diameter dilated colon with no mechanical cause or obstruction transition zone, compressing the urinary bladder and all internal organs (Figure 1). Initial colonoscopic decompression and insertion of the rectal tube failed due to a loaded stool. She underwent laparotomy, total abdominal colectomy with end ileostomy, and full-thickness rectal biopsy (Figure 2). The postoperative recovery was uneventful, and the patient was discharged home on day six postoperatively after stoma care education. Histopathology studies revealed that the patient had hypoganglionosis, and an ileorectal anastomosis was used to close the ileostomy several months later. Her performance level at work increased dramatically, as shown by clinic visits.

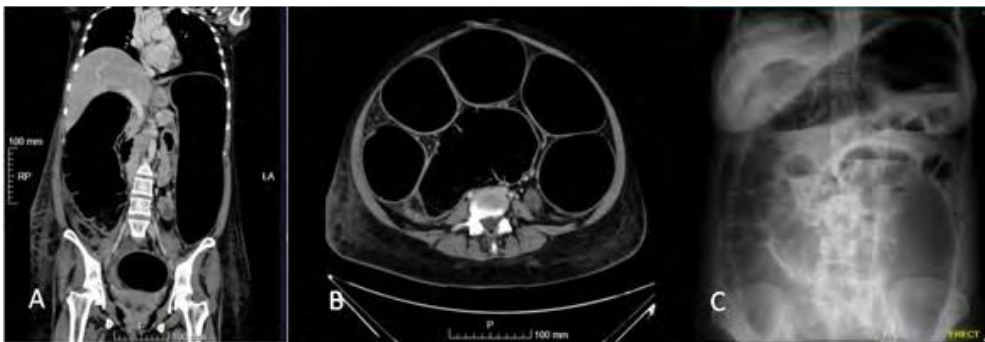
## 4.2. Case 2

The patient is a man who is 21 years old and has never been told he has a long-term illness. Present with a rapid heart rate and severe bloating in the abdomen. The patient's pulse was 145 beats per minute; he was tachypneic and unresponsive, and he required rapid intubation and cardiac resuscitation. The digital rectal examination (DRE) revealed no bowel sounds and a rectum that was full of feces. He was acidotic (PH: 7.01, PCO<sub>2</sub>: 210, HCO<sub>3</sub>: 17.2, lactate: 13.2, WBC: 9.21, HB: 10.6). The colon was enlarged, and bowel enhancement was low, as seen on a CT scan of the abdomen. Bilateral lower lobe lung consolidation and rightward mediastinal displacement are secondary to left-sided distention of the colon. Results of exploratory laparotomies revealed a severely enlarged colon that extended from the cecum to the end of the rectum, compromising the colon's vascularity. Total abdominal colectomy with an end ileostomy is done. The patient was extubated on postoperative day 1 and sent home on postoperative day 9 with stoma care instructions (Figures 3 and 4).

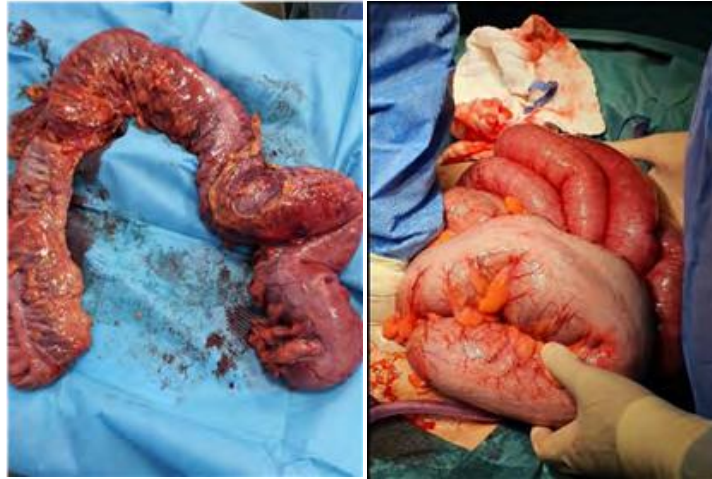## 4.3. Histopathology

**4.3.1. COLON:** Large colon segment measured 130X10X10cm, attached with the end part of ileum measured 4X3X3cm. The colonic segment dilated, and serial cut section grossly unremarkable tissue surface. The appendix measured 7X0.4X0.4cm, the serosa is grayish tan in color with a dilated lumen and focal peritonitis. Ganglion cells are present in the submucosa and muscularis plexi of the ileum and appendix.

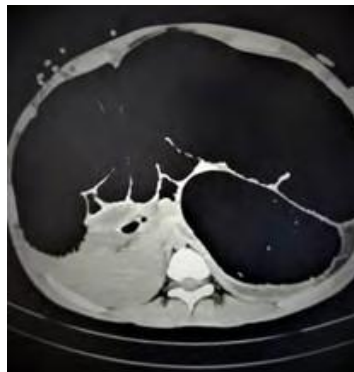
**4.3.2. RECTUM:** Rectal biopsy measures 1 x 0.8 x 0.5 cm and includes mucosa, submucosa and muscularis propria. A calretinin immune-stain showed scanty ganglion cells and focal neural hyperplasia within the myenteric plexus consistent with hypoganglionosis. No ganglion cells are present in the submucosal plexus (Figure 5).



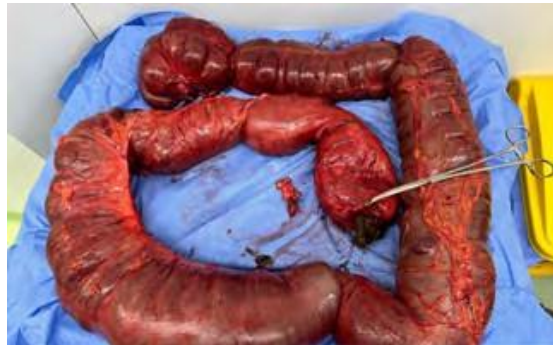**Figure 1:** A) Erect abdominal x-ray displays dilated gas-filled bowel, mainly colonic in distribution with multiple air-fluid levels, no free air under the diaphragm, clear lung bases, and costophrenic angles. B) & C) A CT scan with contrast at different cuts showed marked gas dilatation of the whole large bowel without evidence of a transition point or mechanically obstructing lesion with small free fluid in the pelvis. Diameters of the dilated colon reach up to 12 cm. All upper abdominal organs are compressed against the diaphragm.



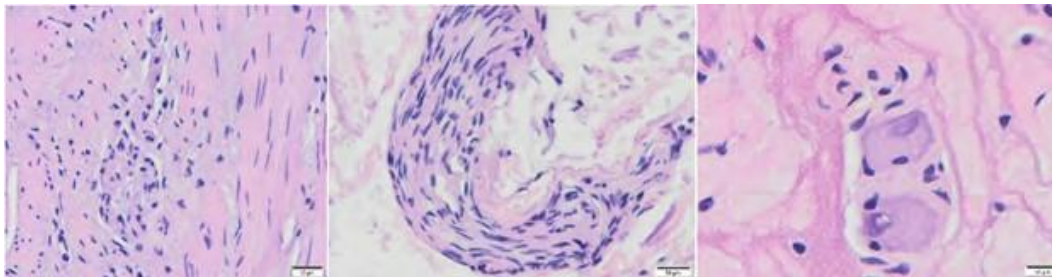
**Figure 2:** Intraoperative finding of spastic dilated colon loaded with stool. No colonic mass or transition zone. Total abdominal colectomy with end ileostomy without on-table lavage or stool leakage.



**Figure 3:** CT scan with contrast at different cuts showed marked gas dilatation of the whole large bowel without evidence of a transition point or mechanically obstructing lesion. Diameters of the dilated colon reach up to 16 cm. All upper abdominal organs are compressed against the diaphragm



**Figure 4:** Total colon showed no colonic mass or transition zone. Total abdominal colectomy with end ileostomy without on-table lavage or stool leakage.



**Figure 5:** Full-thickness rectal biopsy showed scanty ganglion cells and focal neural hyperplasia within the myenteric plexus. No ganglion cells are present in the submucosal plexus. These findings are consistent with hypoganglionosis.

## 5. Discussion

Diverse disorders that manifest in the gastrointestinal system are included under the umbrella term “enteric Neuromuscular Disorder (NMD). The most frequent intestinal innervation disorder is HD, with a prevalence of 1 in 5000 and a female to male ratio of 1 in 4 [6]. An absence of ganglion cells in the neural plexuses of the rectum with varied extension is caused by the failure of craniocaudal migration of neuroblasts during the third month of fetal development [7-8]. When moving from the distal aganglionic segment to the proximal ganglionic segment, an HG segment may serve as a defining feature. A diagnosis of HG may be made if there are fewer than one ganglion per 10 mm or if there are fewer than two neurons per ganglion [9-10]. Meissner’s plexus in the submucosal layer and the Auerbach plexus in the muscular layer of the intestine both have less mature ganglion cells in people with HG [11]. Both the clinical and radiological presentations of intestinal HG are similar to HD. Two forms of HG exist: isolated HG and HD-associated HG [12-13]. The former is further branched into congenital (CIHG) and acquired (AIHG) isolated hypoganglionosis. A nationwide survey revealed intraoperative biopsies were only able to correctly diagnose HG in half of patients, and preoperative diagnosis is typically challenging [14]. The submucosal nerve plexus is normal in isolated HG, but the myenteric ganglia are severely attenuated [15]. Other characteristics include a reduction in lamina propria acetylcholinesterase activity and an enlargement of the muscularis mucosae. Ganglion cell number and size are both reduced at birth in patients with CIHG; however, whereas ganglion cell size does rise with time, ganglion cell quantity does not. In spite of the fact that AIHG often manifests itself as a finding of late onset and is distinguished by the degeneration of ganglion cells in the neural plexi [16]. This inflammatory process may be triggered by a variety of factors, including ischemia, CMV, EBV, multiple sclerosis, and autoimmune illnesses [17-20].

Histological analysis of full-thickness biopsies taken from the rectal area is the gold standard for diagnosis [19]. Nevertheless, suction rectal samples are insufficient for diagnosis because of the heterogeneity in the number and size of submucosal ganglion cells that define intestinal HG. During the course of an emergency operation, a rectal biopsy can be performed, as was the case in our study. It can be used to tell the difference between a completely absent ganglion, as in HD, and a sparse ganglion, as in HG.

Patients with type 1 (focal) HG exhibit a transitional zone, as focal narrowing with few ganglion cells leads to a picture of functional obstruction, which is one way to categorize HG. Type 2 (generalized) HG, in contrast, did not exhibit a transitional zone along with a diffuse decrease in ganglions throughout the intestine [21].

Diagnosing HG histologically is difficult. As the c-kit staining faded, so did the number of interstitial cells in Cajal. Moreover, enlargement of the muscular mucosa and circular muscle, low or absent acetylcholinesterase activity in the lamina propria, and the presence of immature ganglion cells were also found [22]. The diagnostic rea-

gents calcitonin, peripherin, and S-100 are quite helpful. Meier-Ruge demonstrated three findings for the diagnosis. First, the number of nerve cells is only 40% of the normal innervated colon. Secondly, double-space between ganglia. Last but not least, the mean area of the ganglion is three times smaller than the normal innervated colon [23].

Similar to our first case, a mere case of acquired colonic HG and combined esophageal achalasia is described in the literature [20]. A study from South Korea reported 24 patients with HG who had undergone surgery for intractable constipation or chronic pseudo-obstruction [24]. There are few cases reported of HG with an emergency presentation compatible with our second case [25]. Paucity and intermittence of symptoms had allowed for a late diagnosis and ultimate acute expression [26]. Within a short period of time, the first patient underwent ileorectal anastomosis, and more than six months of clinic followup had passed without a return of illness. Next up, we have a second patient who is awaiting stoma revision.

## 6. Conclusion

Colonic hypoganglionosis is a disorder that often goes undiagnosed. Awareness of this rare case scenario can help in enhancing clinical judgment, treating patients, and clustering evidence for such a problem.

## References

1. Aldossary MY, Privitera A, Elzamzami O, Alturki N, Sabr K. A Rare Case of Adult-Onset Rectosigmoid Hypoganglionosis. *Am J Case Rep.* 2018; 19: 557-61.
2. Kwok AM, Still AB, Hart K. Acquired segmental colonic hypoganglionosis in an adult Caucasian male: A case report. *World J Gastrointest Surg.* 2019; 11(2): 101-11.
3. Sreedher G, Garrison A, Novak R, Keisling M, Ganapathy SS. Congenital intestinal hypoganglionosis: A radiologic mimic of Hirschsprung’s disease. *Radiol Case Rep.* 2018; 14(2): 171-174.
4. Qadir I, Salick MM, Barakzai A, Zafar H. Isolated adult hypoganglionosis presenting as sigmoid volvulus: a case report. *J Med Case Rep.* 2011; 5: 445.
5. Dingemann J, Puri P. Isolated hypoganglionosis: systematic review of a rare intestinal innervation defect. *Pediatr Surg Int.* 2010; 26(11): 1111-5.
6. Besnard M, Faure C, Fromont-Hankard G, Ansart-Pirenne H, Peuchmaur M, Cezard JP, et al. Intestinal pseudo-obstruction and acute pandysautonomia associated with Epstein-Barr virus infection. *Am J Gastroenterol.* 2000; 95(1): 280-4.
7. Badner JA, Sieber WK, Garver KL, Chakravarti A. A genetic study of Hirschsprung disease. *Am J Hum Genet.* 1990; 46(3): 568-80.
8. Puri P, Gosemann JH. Variants of Hirschsprung disease. *Semin Pediatr Surg.* 2012; 21(4): 310-8.
9. Knowles CH, De Giorgio R, Kapur RP, Bruder E, Farrugia G, Geboes K, et al. Gastrointestinal neuromuscular pathology: guidelines for histological techniques and reporting on behalf of the Gastro 2009 International Working Group. *Acta Neuropathol.* 2009; 118(2): 271-301.

10. Kobayashi H, Yamataka A, Lane GJ, Miyano T. Pathophysiology of hypoganglionosis. *J Pediatr Gastroenterol Nutr.* 2002; 34(2): 231-5.
11. Knowles CH, De Giorgio R, Kapur RP, Bruder E, Farrugia G, Geboes K, et al. Gastrointestinal neuromuscular pathology: guidelines for histological techniques and reporting on behalf of the Gastro 2009 International Working Group. *Acta Neuropathol.* 2009; 118(2): 271-301.
12. Schäppi MG, Staiano A, Milla PJ, Smith VV, Dias JA, Heuschkel R, et al. A practical guide for the diagnosis of primary enteric nervous system disorders. *J Pediatr Gastroenterol Nutr.* 2013; 57(5): 677-86.
13. Do MY, Myung SJ, Park HJ, Chung JW, Kim IW, Lee SM, et al. Novel classification and pathogenetic analysis of hypoganglionosis and adult-onset Hirschsprung's disease. *Dig Dis Sci.* 2011; 56(6): 1818-27.
14. Watanabe Y, Kanamori Y, Uchida K, Taguchi T. Isolated hypoganglionosis: results of a nationwide survey in Japan. *Pediatr Surg Int.* 2013; 29(11): 1127-30.
15. Dingemann J, Puri P. Isolated hypoganglionosis: systematic review of a rare intestinal innervation defect. *Pediatr Surg Int.* 2010; 26(11): 1111-5.
16. Taguchi T, Masumoto K, Ieiri S, Nakatsuji T, Akiyoshi J. New classification of hypoganglionosis: congenital and acquired hypoganglionosis. *J Pediatr Surg.* 2006; 41(12): 2046-51.
17. Gabbani T, Marsico M, Marocchi M, Biagini MR. Isolated hypoganglionosis in young man with autism. *Dig Liver Dis.* 2017; 49(1): 104.
18. Taguchi T, Masumoto K, Ieiri S, Nakatsuji T, Akiyoshi J. New classification of hypoganglionosis: congenital and acquired hypoganglionosis. *J Pediatr Surg.* 2006; 41(12): 2046-51.
19. Holland-Cunz S, Göppl M, Rauch U, Bär C, Klotz M, Schäfer KH. Acquired intestinal aganglionosis after a lytic infection with varicella-zoster virus. *J Pediatr Surg.* 2006; 41(3): e29-31.
20. Taguchi T, Masumoto K, Ieiri S, Nakatsuji T, Akiyoshi J. New classification of hypoganglionosis: congenital and acquired hypoganglionosis. *J Pediatr Surg.* 2006; 41(12): 2046-51.
21. Kim HJ, Kim AY, Lee CW, Yu CS, Kim JS, Kim PN, et al. Hirschsprung disease and hypoganglionosis in adults: radiologic findings and differentiation. *Radiology.* 2008; 247(2): 428-34.
22. Do MY, Myung SJ, Park HJ, Chung JW, Kim IW, Lee SM, et al. Novel classification and pathogenetic analysis of hypoganglionosis and adult-onset Hirschsprung's disease. *Dig Dis Sci.* 2011; 56(6): 1818-27.
23. Holland SK, Hessler RB, Reid-Nicholson MD, Ramalingam P, Lee JR. Utilization of peripherin and S-100 immunohistochemistry in the diagnosis of Hirschsprung disease. *Mod Pathol.* 2010; 23(9): 1173-9.
24. Do MY, Myung SJ, Park HJ, Chung JW, Kim IW, Lee SM, et al. Novel classification and pathogenetic analysis of hypoganglionosis and adult-onset Hirschsprung's disease. *Dig Dis Sci.* 2011; 56(6): 1818-27.
25. Pescatori M, Mattana C, Castiglioni GC. Adult megacolon due to total hypoganglionosis. *Br J Surg.* 1986; 73(9): 765.
26. Do MY, Myung SJ, Park HJ, Chung JW, Kim IW, Lee SM, et al. Novel classification and pathogenetic analysis of hypoganglionosis and adult-onset Hirschsprung's disease. *Dig Dis Sci.* 2011; 56(6): 1818-27.